



**KAMAL R. CHÉMALI, MD**

Department of Neurology, The Cleveland  
Clinic Foundation

**BRYAN TSAO, MD**

Department of Neurology, The Cleveland  
Clinic Foundation

# Electrodiagnostic testing of nerves and muscles: When, why, and how to order

## ■ ABSTRACT

The electrodiagnostic examination can provide essential information in cases of suspected peripheral nervous system disorders or injury. To optimize the yield of this test, one must have a basic understanding of how it works, when and how to order it, and its inherent limitations.

## ■ KEY POINTS

The electrodiagnostic examination consists of two main parts: a needle electrode examination and a nerve conduction study. These provide complementary information and are usually done together.

The needle electrode examination will detect loss or degeneration of axons, whereas the nerve conduction study can detect segmental demyelination.

The usefulness of the electrodiagnostic examination depends on when it is performed: in general, it should be no less than 21 days after the injury or the onset of symptoms.

There are few if any serious complications associated with these tests. Bleeding is minimal, as are skin infections, even in diabetic and immune-compromised patients.

**E**LECTRODIAGNOSTIC TESTING is a powerful tool for diagnosing and developing treatment plans for patients with diseases of the peripheral nervous system and muscles. It generally includes both a needle electrode examination and a nerve conduction study and can help pinpoint the location of the problem—ie, in the motor neurons, nerve roots, peripheral nerves, neuromuscular junction, or muscle—and establish the underlying process in these disorders.

This testing provides the most valuable diagnostic information when it is combined with a clinical diagnosis. In the case of a complex clinical picture, it is best to clarify the diagnosis by obtaining a neurologist's opinion before ordering the electrodiagnostic testing.

But when and how to use electrodiagnostic testing is not always clear. For instance, ordering the tests too soon after some injuries may produce inconclusive results.

This review explains, in practical terms for primary care physicians, the anatomic and physiologic bases of electrodiagnostic testing, how it can be put to best use, and how to order it.

In this article, we will use the term “electrodiagnostic.” Although many still refer to this testing as electromyographic (or EMG), this usage is now being discouraged because it can be confusing, often meaning only the needle electrode part of the evaluation.

## ■ TWO TYPES OF INJURY

The two major types of peripheral nerve injury that an electrodiagnostic examination can detect are:

TABLE 1

## Electrodiagnostic findings in common peripheral nervous system disorders

### Anterior horn cell disorders

Amyotrophic lateral sclerosis (progressive motor neuron disease)

Poliomyelitis

Nerve conduction study (NCS): Normal sensory and often reduced motor responses

Needle electrode examination (NEE)\*: Active, chronic, and reinnervating neurogenic changes along with fasciculation potentials in multiple myotomes

### Nerve root disorders

Compressive radiculopathy (disk disease)

Inflammatory radiculopathy (autoimmune, viral)

NCS: Normal sensory response and normal to low motor responses in most

NEE\*: If motor radiculopathy is present, varying amounts of active and chronic neurogenic changes in corresponding myotomes

### Plexus disorders (brachial, lumbar)

Depending on the location and severity of the lesion:

NCS shows varying degrees of reduced sensory and motor responses;

NEE shows neurogenic changes

### Peripheral nerve disorders

Focal neuropathy (axon loss or demyelination), eg, median, ulnar, radial neuropathy

Depends on location of neuropathy and predominant pathophysiology: eg, demyelinating changes on NCS for median neuropathy at the wrist vs axon loss for peroneal neuropathy at the fibular head or ulnar neuropathy at the elbow

Generalized neuropathy (axon loss or demyelination)

Axon loss:

NCS shows distally reduced or absent responses (sensory > motor) and relatively preserved conduction velocities;

NEE often shows chronic and active neurogenic changes in a distal-to-proximal distribution

Acquired demyelination:

NCS shows evidence of demyelinating conduction block, nonuniform conduction slowing, and increased waveform dispersion;

NEE may demonstrate neurogenic changes

### Neuromuscular junction disorders

Myasthenia gravis

Lambert-Eaton myasthenic syndrome (200% amplitude increment on fast-rate repetitive stimulation)

Botulism

Motor amplitude decrement on slow repetitive stimulation studies, motor unit instability, and occasionally myopathic units on NEE

### Myopathy (necrotizing or non-necrotizing)

NCS: normal sensory and motor responses in most cases; very severe myopathies may have reduced motor responses

NEE\*: small and complex (polyphasic) motor potential units with early recruitment; presence of active denervation (fibrillation potentials) indicates a necrotizing or inflammatory component

\*Most useful test in this condition

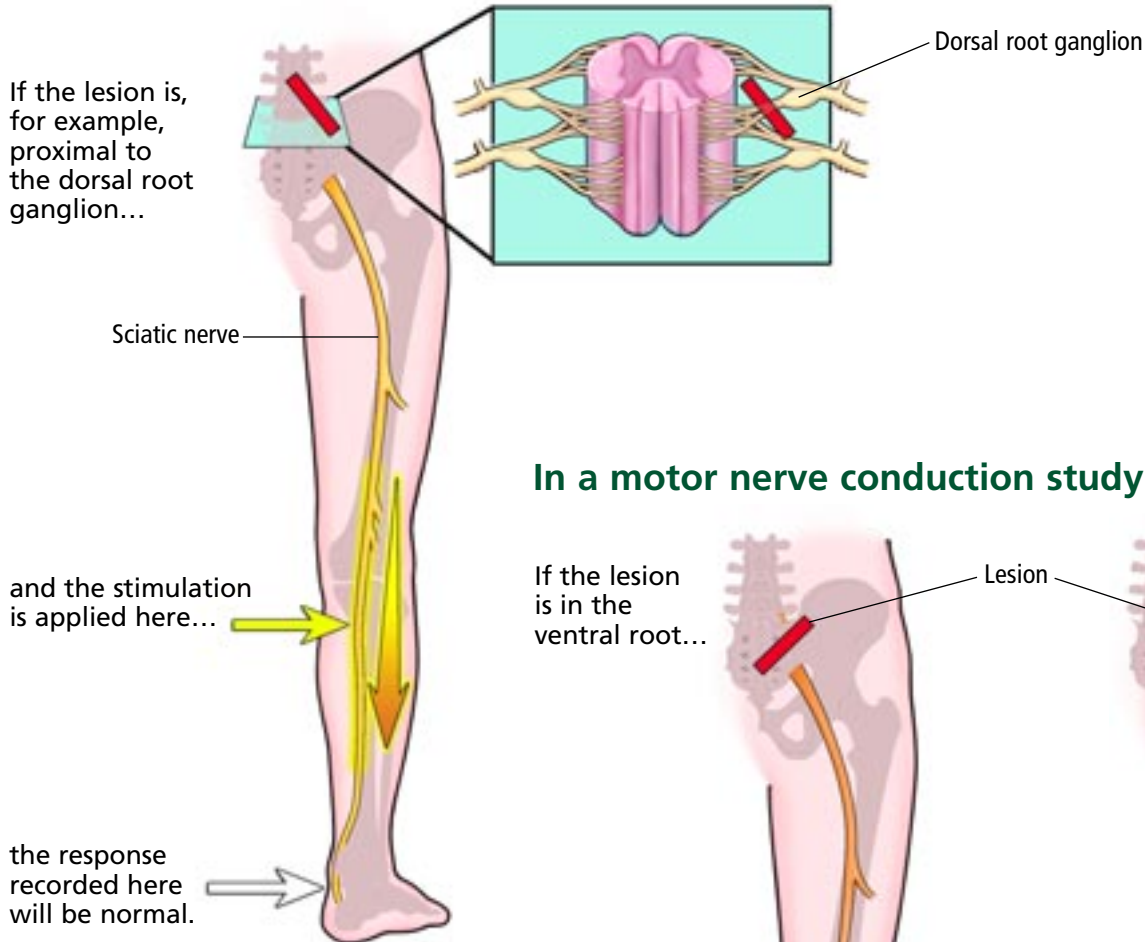
- **Axon degeneration** (or axon loss), which is best detected by a needle electrode examination (see below), but only after about 21 days from the time of injury. Causes of axon loss include severe compression or trauma of the nerve, ischemia of the nerve, and inflammation.

- **Segmental demyelination** (a focal conduction disturbance along an intact axon).<sup>1</sup> This can be detected by a nerve conduction study almost immediately after the onset of the disease process. Causes of demyelination include mild to moderate compression of the

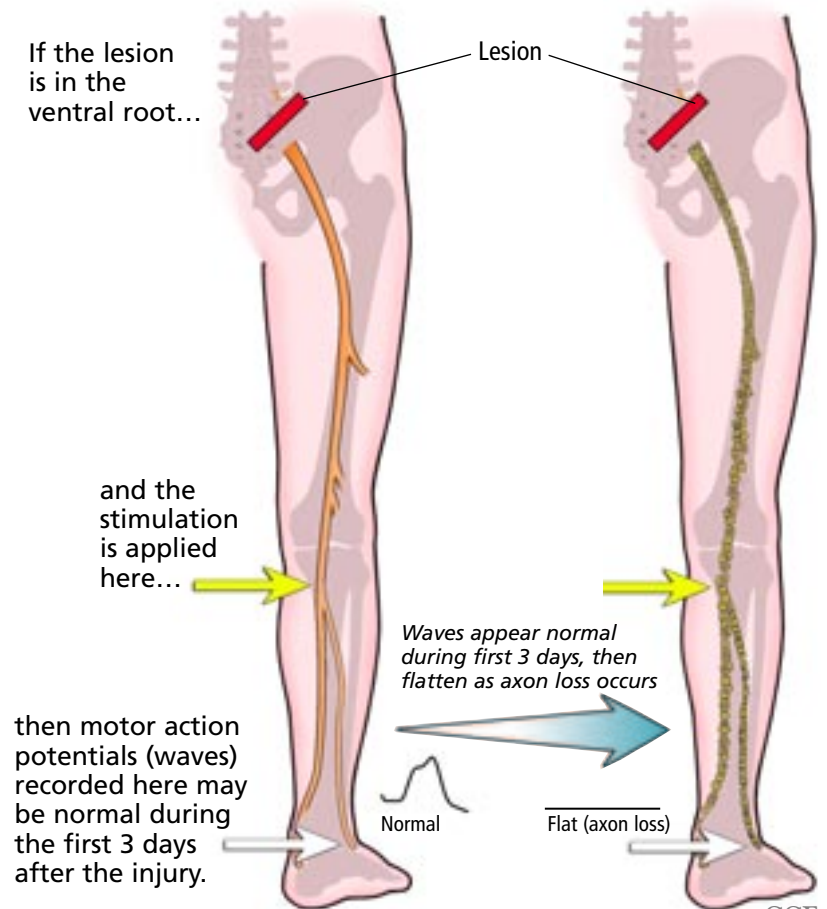


# Nerve conduction studies in radiculopathy

## In a sensory nerve conduction study...



## In a motor nerve conduction study...



CCF  
©2005

FIGURE 1

TABLE 2

### General advantages and limitations of the electrodiagnostic examination

#### Nerve conduction studies

##### Advantages

- Subclinical detection of demyelinating lesions
- Less uncomfortable, requires less cooperation
- Highly sensitive in differentiating axon loss from demyelination
- Can locate segmental demyelinating lesions

##### Limitations

- Routine studies primarily evaluate distal nerves (limited portion of peripheral nervous system)
- Certain sensory responses may be lost with age
- Less sensitive for axon loss

#### Needle electrode examination

##### Advantages

- Subclinical detection of axon loss lesions
- Allows widespread examination of peripheral nervous system
- Primary means to detect muscle disorders

##### Limitations

- Requires patient cooperation (generally more uncomfortable)
- Does not evaluate sensory fibers
- Insensitive for demyelinating lesions

Electrodiagnostic testing should include nerve conduction studies and a needle electrode exam

nerve and autoimmune disorders (including primary demyelinating polyneuropathy).

Clinically, axon loss and segmental demyelination can appear similar. Both can cause weakness. However, their electrical features and prognoses are very different. Hence the value of the electrodiagnostic examination in determining the type of injury.

TABLE 1 lists disorders in which the electrodiagnostic examination plays an important diagnostic role.

#### ■ TWO PARTS OF THE EXAMINATION

The electrodiagnostic examination includes two separate parts: the nerve conduction study and the needle electrode examination. Each has distinct advantages and limitations (TABLE 2), but together they play complementary roles in a comprehensive evaluation of the peripheral nervous system. For this reason, most electrodiagnosticians never perform one without the other, except in a few situations in which nerve conduction studies alone are performed earlier than 21 days from the onset of symptoms.

#### Nerve conduction studies

Nerve conduction studies include studies of both sensory and motor nerve conduction (FIGURE 1).

**Sensory nerve conduction studies** are usually performed by placing a recording electrode on the skin directly above a sensory nerve. An electrical stimulus is applied proximally at a defined distance from the recording electrode, producing a detectable waveform called the *sensory nerve action potential*.

Sensory nerve fibers have their cell bodies in the dorsal root ganglia within the intervertebral foramen.<sup>2</sup> Lesions proximal to the ganglion (such as radiculopathies) usually do not affect sensory nerve action potentials.<sup>3</sup> In contrast, for lesions distal to the dorsal root ganglion (plexopathies, neuropathies), sensory nerve action potentials may be reduced or absent.

Thus, sensory studies are useful, for instance, in distinguishing between disk disease and carpal tunnel syndrome as a cause of finger numbness.

**Motor nerve conduction studies** are performed by placing a recording electrode directly over the belly of the muscle and stimulating the nerve proximally. The muscle fibers depolarize, producing a waveform called a *compound motor action potential*. This potential may be reduced if motor axons are damaged. This test is not as sensitive as the needle electrode examination (described below) in detecting very mild motor axon loss, but it is more reliable for quantifying the amount of axon loss.

**Special studies.** More refined nerve conduction studies include the late responses, mixed sensory and motor conduction, and repetitive stimulation studies. These specialized tests are used when specific diagnoses (such as radiculopathies, peripheral neuropathies, or myasthenia gravis) are suspected, and are only briefly discussed in the section on indications for ordering the electrodiagnostic examination (see below).

#### The needle electrode examination

The needle electrode examination provides information about the motor unit.

Typically, small-gauge needles (usually 23-gauge to 25-gauge) are inserted into the muscle to be studied to analyze its electrical activ-



ity (specifically, its motor unit action potentials) at rest and during voluntary activation. The electrical activity is displayed on an oscilloscope or computer monitor and is also played over a loudspeaker for simultaneous visual and auditory analysis.

If there is axon loss or ongoing denervation, the muscle typically shows abnormal spontaneous activity, called *fibrillation potentials*. However, this sign is not specific and can be seen in both axon loss and certain types of myopathic disease.

During activation, the configuration (ie, duration and amplitude) of motor unit action potentials on the monitor and their pattern of recruitment (ie, the number of units and their rate of firing during muscle contraction) enable us to distinguish a number of diseases that affect different parts of the motor unit.

For example, in a patient with back pain and bilateral proximal leg weakness, the differential diagnosis includes high lumbar radiculopathy (or lumbar canal stenosis) vs myopathy. In both cases, nerve conduction studies can be normal: intraspinal diseases and myopathies typically spare sensory nerve action potentials, whereas mild motor axon loss or mild myopathies can spare compound motor action potentials.

**Single-fiber electromyography** is a very sensitive test of the neuromuscular junction and can be very useful in the diagnosis of myasthenia gravis if the results of repetitive nerve stimulation studies are equivocal; however, it lacks specificity, and it can be abnormal in certain myopathies and conditions that cause denervation, such as amyotrophic lateral sclerosis.

### ■ WHEN IS THE BEST TIME TO TEST?

The usefulness of electrodiagnostic testing partly depends on how long after the onset of symptoms it is performed.

#### **Time-dependent changes after injury**

Nerve conduction studies and needle electrode examinations each show characteristic time-dependent changes in response to axon loss and demyelinating lesions.

For instance, in acute nerve transection (axon-loss lesion), if we stimulate and record

across the lesion, we get no response. However, if we stimulate the distal disconnected segment and record over it or over the muscle it innervates, we can still get a sensory or motor response for several days before Wallerian degeneration occurs.

The amplitude of the compound motor action potential falls to a minimum by 3 days after injury, or 10 days for sensory nerve action potentials. On the needle electrode examination, fibrillation potentials—the hallmark of axon degeneration—are seen only after 21 days.<sup>4</sup> Before that, only a reduction in motor unit recruitment is seen, but motor unit configuration remains normal.

A common example is acute lumbosacral radiculopathy. At the onset of symptoms, an electrodiagnostic examination will probably be normal. A study performed 3 to 21 days later may show lower amplitudes of compound motor action potentials at certain foot muscles and absent H reflexes, but these findings alone are not diagnostic. Only after 21 days, when fibrillation potentials have developed in muscles innervated by the affected root (including paraspinal muscles), can a firm diagnosis and determination of the lesion type be made by needle examination.

Of note: these changes will occur only if the motor (ventral) root is involved. If the lesion affects only the sensory (dorsal) root, such as in a pure sensory lumbosacral radiculopathy, the electrodiagnostic examination will remain normal even after 21 days.

In severe segmental demyelinating lesions, such as after prolonged nerve compression or primary demyelinating polyneuropathies, the electrical signal cannot get through the affected nerve segment, a condition called “conduction block.” Nerve conduction studies will show no response across the affected segment, and a needle electrode examination will reveal only a dropout or a reduction of motor unit recruitment. If the study is performed before 21 days, these findings could mimic those of axon loss.

#### **In most cases, wait 21 days to test**

For most cases, therefore, the electrodiagnostic examination should be performed only after 21 days from the time of injury.

Exceptions to this rule include cases in

**Timing is critical: testing earlier is not better**



which it is important to locate where the lesion is along the nerve (which becomes impossible in axon loss injuries once wallerian degeneration has occurred), or to differentiate between axon loss and demyelinating lesions for prognostic purposes. It is also important when primary demyelination is present. In such cases, nerve conduction studies alone can be done early, but should be repeated along with a needle electrode examination 21 days later.

**Example:** A young, healthy woman presents with an acute wrist drop, noticed on awakening. This is most probably a compressive radial neuropathy at the radial groove in the lateral mid-arm, which could be either a demyelinating or an axon-loss lesion.

Nerve conduction studies performed very soon after the onset will detect a conduction block across the radial groove, but this finding, although helpful for locating the lesion, does not tell us the type of injury. A repeat test more than 21 days after the onset will reveal either of the following:

- Improvement or disappearance of the conduction block (a response is obtained distal to the block when stimulating proximally) and a normal needle electrode examination. In this case, the injury is most probably a demyelinating lesion in the process of recovery, with a good prognosis.
- Persistent absence of the response when stimulating proximal to the groove, with loss of the previously intact response when stimulating distal to the groove. These findings reflect wallerian degeneration in the distal stump. Therefore, there has been axon loss, and the prognosis is more guarded. The finding of fibrillation potentials on the needle electrode examination will further confirm axon loss.

Occasionally, a few fibrillation potentials are seen in a primary demyelinating lesion, owing not to demyelination itself but to secondary axon loss. In other acute mononeuropathies (peroneal and facial, for example) and in early Guillain-Barré syndrome, early nerve conduction studies may also be helpful. Even in these special cases, it is preferable not to perform the electrodiagnostic examination less than 3 days from the onset of symptoms.

### But don't wait too long

On the other hand, the yield for diagnosing most neuromuscular disorders diminishes with time. For example, in radiculopathy the needle electrode examination is critical for diagnosis, but findings such as fibrillation potentials can disappear with time, even when clinical signs and symptoms persist. The frequency of false-negative studies increases in cervical radiculopathies of greater than 6 months' duration<sup>5</sup> and lumbosacral radiculopathies of more than 12 to 18 months' duration.

### ■ INDICATIONS FOR TESTING

Before deciding whether an electrodiagnostic examination is needed, it is essential to clinically determine where the problem is. Although an electrodiagnostic examination can be very useful in diagnosing a focal or a generalized problem, you need to tell the electrodiagnostician what you are looking for. The following is a general approach.

#### Determine whether the process is focal or generalized

If the process is focal, determine which limb and side is most affected. Then, if possible, determine clinically which nerve is involved. In general, focal lesions require complete study of the symptomatic arm or leg, with limited comparison of the contralateral side. In contrast, generalized conditions (eg, myopathy, polyneuropathy, myasthenia gravis) require studying an arm and leg on the same side.

**Carpal tunnel syndrome: a common focal problem.** If a patient has numbness of the right index finger and middle finger that wakes him or her up at night, and has a positive Tinel sign, ie, distal tingling in the first three digits (median nerve distribution) when the anterior (ventral) aspect of the wrist is percussed, then the most likely diagnosis is a focal distal median mononeuropathy such as carpal tunnel syndrome. A cervical radiculopathy is less likely. In ordering the test, you should indicate that you suspect the patient has "right median neuropathy (carpal tunnel syndrome)." The terms are not synonymous: median mononeuropathy is an electrical diagnosis, whereas carpal tunnel syndrome is a clinical entity caused by entrapment of the median nerve at the carpal tunnel.

**Try to determine if the problem is focal or generalized; then order testing**



It can be caused by acute or chronic repetitive trauma to the wrist, diabetes, hypothyroidism, pregnancy, osteoarthritis, rheumatoid arthritis, amyloid deposition, or other conditions. Electrically, these distal median mononeuropathies are usually localized at or distal to the wrist.

Not every laboratory performs a needle electrode examination if nerve conduction studies are diagnostic of a distal median mononeuropathy consistent with carpal tunnel syndrome. However, the needle electrode examination is a very powerful addition to nerve conduction studies for the diagnosis of radiculopathies.

Because some patients have both carpal tunnel syndrome and radiculopathy of the sixth or seventh cervical vertebra,<sup>6</sup> or they have superimposed conditions that mimic carpal tunnel syndrome (eg, proximal median neuropathies, true neurogenic thoracic outlet syndrome), and because these conditions can present with similar clinical manifestations (ie, pain and dysesthesia of the first three digits), we believe that a needle electrode examination should be performed as part of every workup for carpal tunnel syndrome, especially in the elderly. Otherwise, the patient might undergo carpal tunnel surgery, which would fail to resolve the symptoms because they are in fact caused by unrecognized cervical root disease or other conditions.

To avoid this unnecessary surgery, all patients referred to our laboratory with a diagnosis of carpal tunnel syndrome undergo both a nerve conduction study and a needle electrode examination, to look mainly for root disease, even if an evaluation for cervical radiculopathy is not ordered.

**Lumbosacral radiculopathy: another common focal problem.** Back pain that radiates down the left thigh with weakness of the left dorsiflexors and evertors of the foot suggests L5 lumbosacral radiculopathy. Therefore, the test order should indicate “left lumbosacral radiculopathy, L5–S1.” The report should mention whether the radiculopathy is active or chronic (based mainly on the presence or absence of fibrillation potentials and the morphology of the motor units), and it will state the segment or root where the intraspinal canal lesion is.

Of note: an electrodiagnostic examination can detect only motor radiculopathies (generally associated with weakness). A sensory radiculopathy (pain without weakness) will not affect the sensory responses because the radicular lesion is proximal to the dorsal root ganglion.

**Generalized problems** usually arise within the intraspinal canal (eg, amyotrophic lateral sclerosis), peripheral nerves (eg, polyneuropathy), neuromuscular junction (eg, myasthenia gravis), or muscle (eg, myopathy). In generalized disorders that appear symmetric, by convention the dominant arm, leg, and related paraspinals (determined by which is the dominant hand) are studied.

For instance, symmetric numbness and hypersensitivity with a gradient of severity from both feet to below both knees suggests a peripheral polyneuropathy. If the symptoms are asymmetric, the more symptomatic side is studied. The order should indicate “right generalized polyneuropathy.” If a specific polyneuropathy is suspected (eg, pure sensory polyneuropathy or demyelinating polyneuropathy), the request should contain this information.

Generalized proximal weakness may suggest a myopathy or neuromuscular junction disorder. If you suspect myopathy, then indicate “right or left myopathy” on the order. If myasthenia gravis is suspected, “right or left neuromuscular junction disorder—myasthenia gravis” should be indicated.

### Tailoring the examination

Although laboratories have protocols for various diagnoses, the electrodiagnostic examination is tailored to each patient.

For example, a routine evaluation of polyneuropathy usually entails studying one arm and the leg on the same side; however, to evaluate the brachial plexus, one or both arms are studied (the contralateral arm is studied for comparison). It is therefore important to mention the suspected diagnosis rather than merely requesting a general limb survey, even though the actual diagnosis may prove different from the suspected one.

For another example, if a patient is referred for a carpal tunnel evaluation but the electrodiagnostic examination test indicates a more extensive process (eg, a superimposed

**When ordering these tests, mentioning the suspected diagnosis helps tailor the examination**

polyneuropathy or cervical radiculopathy), additional studies are needed to better define the more generalized problem. In many cases, owing to time limitations, the patient will have to come back to the laboratory for this further evaluation.

### ■ THE VALUE OF TESTING IN SPECIFIC DISORDERS

#### Anterior horn cell disorders: Testing is sensitive but not specific

The electrodiagnostic examination is very valuable in detecting generalized disorders such as amyotrophic lateral sclerosis (progressive motor neuron disease), poliomyelitis, and other processes related to anterior horn cell degeneration (eg, spinal muscular atrophy, cord ischemia, and tumors).<sup>7</sup>

The examination is very sensitive for axon loss, but it is not specific: eg, it cannot differentiate between a generalized anterior horn cell disorder and polyradiculopathy (due to multiple disk disease or to other lesions of the spinal roots), because both of these lesions are proximal to the dorsal root ganglia and therefore do not disturb the distal sensory responses. Thus, the interpretation may read: "There is evidence of a generalized intraspinal canal disorder manifested by active and chronic motor axon loss, consistent with (not 'diagnostic of') a generalized anterior horn cell disorder."

#### Single and multiple radiculopathies: Testing is useful in differential diagnosis

Electrodiagnostic examination is useful in finding the level of a radiculopathy and determining its chronicity and degree of severity. This is especially helpful in differentiating disease processes that are clinically indistinguishable.

For example, as mentioned previously, carpal tunnel syndrome often presents with intermittent or constant paresthesia in the median nerve distribution, as can a C7 cervical radiculopathy. Similarly, a C8 cervical radiculopathy can be very difficult to distinguish clinically from an ulnar neuropathy. However, their electrodiagnostic features are dissimilar. The electrodiagnostic examination is sensitive for motor radiculopathies but is nonspecific as to the cause, as root injury from any structural lesion (eg, disk herniation,

tumor encroachment, scarring) can produce similar electrical findings.<sup>8</sup>

#### Spinal canal stenosis: Consider MRI

Spinal canal stenosis often produces bilateral abnormalities and is electrically indistinguishable from multilevel radiculopathies.

If sensory nerve conduction studies are normal but there are signs of denervation on the motor nerve conduction study and the needle electrode examination, the process is usually intraspinal. However, with age (usually after age 60), sensory potentials in the lower extremities tend to decrease in amplitude and eventually disappear. Therefore, the electrical diagnosis of intraspinal canal pathology becomes difficult and sometimes impossible in elderly patients, in whom electrodiagnostic studies cannot reliably distinguish between a peripheral polyneuropathy and intraspinal canal disease.

Since lumbar stenosis occurs mainly in the elderly, these considerations make the electrodiagnostic examination less important than magnetic resonance imaging for diagnosing this condition.

#### Neck or low-back pain: Consider the history and examination

Whether to obtain an electrodiagnostic examination in cases of neck or low back pain depends strongly on the clinical history and examination, regardless of the presence or absence of radicular symptoms.

If there is cervical or lumbosacral radiculopathy, we consider the duration of the symptoms and the neurological findings. If the symptoms have lasted less than a year, are progressive, and are associated with motor weakness, the yield of the electrodiagnostic examination is optimal. On the other hand, if symptoms have lasted more than a year and pain without weakness is the primary complaint, especially if the symptoms are intermittent, the yield of the test is generally low and we would not recommend it.

#### Brachial and lumbosacral plexopathies: Extensive study needed

The electrodiagnostic examination can reliably distinguish between plexus lesions and more proximal root or spinal cord abnormali-

**For certain conditions, the history, physical examination, and MRI may offer useful information**





ties.<sup>9</sup> In a plexopathy, the sensory nerve action potentials in the upper or lower extremities are generally affected, but they remain normal in a radiculopathy or spinal cord lesion. The evaluation of these disorders is complex and requires additional nerve conduction studies and a more extensive needle electrode examination.

### **Mononeuropathies: Ulnar is a challenge**

One of the most common reasons for ordering an electrodiagnostic examination is to determine the type, location, and severity of entrapment neuropathies. These include but are not limited to distal median neuropathies, ulnar neuropathies at the elbow, radial neuropathies, and peroneal neuropathies.

The examination is generally very sensitive for determining the type of the lesion within these peripheral nerves (ie, axon loss or demyelination). As for locating the lesion, the task is relatively simple in demyelinating diseases (seen in most median neuropathies at or distal to the wrist), but more complicated in axonal lesions. Certain neuropathies (especially ulnar) often defy precise localization.

Testing can measure the electrical severity of the lesion, which often (but not always) correlates with clinical severity.<sup>10</sup> The electrical severity generally depends on the amount of axon loss. Most distal median neuropathies are of the demyelinating type, but axon loss can occur in certain circumstances, reflecting the severity of the entrapment.<sup>11</sup> In these cases the electrodiagnostic examination plays a major role in determining the need for surgery. However, the degree of impairment needed to prompt surgery for carpal tunnel syndrome or ulnar neuropathy at the elbow is still controversial.<sup>12-14</sup>

The value of electrodiagnostic testing in detecting cranial neuropathies (including facial nerve neuropathies) and more proximal neuropathies depends on the location of the affected nerve and the type and duration of the lesion. The trigeminal and facial nerves are assessed via the blink reflex and facial nerve stimulation. A variety of disorders of the cranial nerves (eg, Bell palsy) and the brainstem (acoustic neuroma) have characteristic patterns of abnormalities.<sup>15</sup>

### **Peripheral polyneuropathies:**

#### **Only large fibers detected**

The electrodiagnostic examination is helpful in establishing whether a peripheral polyneuropathy is present, its severity and chronicity, and whether the underlying process is axon loss (eg, diabetic polyneuropathy) or demyelination (eg, Guillain-Barré syndrome). Characteristic findings also help in classifying the neuropathy as hereditary<sup>16</sup> or acquired.<sup>17</sup>

The electrodiagnostic examination is most useful in detecting large-fiber neuropathies (moderate and large myelinated axons) but does not provide information on pure small-fiber abnormalities (thin, poorly myelinated, or unmyelinated axons), which are associated with multiple conditions, the most common probably being early diabetes mellitus.<sup>18</sup>

### **Neuromuscular junction defects:**

#### **Consider antibody testing**

The sensitivity of the electrodiagnostic examination in myasthenia gravis, the myasthenic syndrome (Lambert-Eaton myasthenic syndrome), and other presynaptic disorders (eg, botulism) is around 70% in the hands of an experienced electrodiagnostician. In general, the yield is highest if limb weakness is present and lowest when symptoms are confined to the ocular and bulbar muscles. The main technique used is repetitive nerve stimulation, but the needle electrode examination may show motor unit instability.<sup>19</sup>

The electrodiagnostic examination is no longer the gold standard diagnostic test for myasthenia gravis or Lambert-Eaton myasthenic syndrome since the advent of testing for acetylcholine receptor antibody and anti-V/Q calcium channel antibody. However, it still can be used to help diagnose these conditions pending results of antibody titers, or when the results are unavailable. An exception is seronegative or pure ocular myasthenia gravis, for which single-fiber electromyography remains the gold standard test.

### **Myopathies:**

#### **Usefulness varies, but guides biopsy**

The electrodiagnostic examination plays an important role in the diagnosis of myopathic disorders despite limitations that make it variably successful in determining the presence of

**In peripheral polyneuropathies, electrodiagnostic testing helps determine if the problem is hereditary or acquired**

a primary muscle disease.

Abnormalities are most often detected on the needle electrode examination, which shows myopathic motor unit action potentials, but the sensitivity of the test depends on the nature and severity of the disorder. These electrical abnormalities can be nonspecific, because myopathic motor unit action potentials can be seen in neurogenic processes when the denervated muscle is undergoing early reinnervation (they are called “nascent units”). They can also be seen in neuromuscular junction defects and demyelinating neuropathies.<sup>20</sup>

The needle electrode test is useful in determining whether a process is neurogenic or myopathic, eg, a bilateral high lumbar radiculopathy vs a myopathy. Both conditions can cause proximal muscle weakness in the lower extremities. In radiculopathy, the needle electrode examination will show neurogenic changes in motor unit action potentials in the proximal muscles—eg, fibrillations, long-duration and large-amplitude motor unit action potentials, and decreased recruitment. On the other hand, in myopathy, the test will show myopathic changes (short-duration and small-amplitude motor unit action potentials) and early recruitment.

The test also helps in differentiating between a necrotizing (inflammatory) myopathy such as polymyositis, dermatomyositis, or inclusion body myositis, and a non-necrotizing myopathy such as steroid myopathy or muscular dystrophy.

Moreover, testing helps determine which muscle distribution is most affected and, therefore, most appropriate for biopsy. This is why we recommend it before proceeding to a muscle biopsy. However, to avoid false-positive results due to muscle damage by the electrodiagnostic examination needle, biopsy should be done at least 1 to 2 months after the needle electrode examination, or should be done on the opposite side.

#### ■ LIMITATIONS OF ELECTRODIAGNOSTIC TESTING

##### Testing is operator-dependent

Laboratories differ, and we often cannot compare their findings directly. Each laboratory

uses different methods, measurements, and normal values. Moreover, the examiner must have a certain degree of clinical and technical expertise.<sup>1</sup> For these reasons, we may repeat an electrodiagnostic examination done elsewhere, particularly if the clinical diagnosis is unclear.

Individual electrodiagnostic examination laboratories should establish normative data for nerve conduction studies, stratified by patient’s age, skin temperature, and nerve conduction study measurement techniques.

Unfortunately, there are no uniform standards by which to judge an electrodiagnostician’s expertise. Several professional boards ensure a certain degree of reliability. Since a main limiting factor of the electrodiagnostic examination still lies in the expertise of the person performing the tests, it is important that the referring physician have some knowledge of the qualifications of the electrodiagnostician prior to referral.

##### Elderly patients lose sensory nerve conduction in the legs

Both the nerve conduction study and the needle electrode examination are affected by several physiologic factors.

In particular, patients age 60 and older present challenges in assessing the lower extremities. In general, older patients start to lose some sensory nerve conduction, and the thresholds for normal and abnormal criteria begin to merge. This trend makes it harder to evaluate polyneuropathy or lumbosacral radiculopathy in the elderly.

##### Concomitant diseases can reduce accuracy

The coexistence of chronic or active disease and multiple peripheral nerve disorders limits the diagnostic accuracy of the examination.

Examples include remote poliomyelitis with superimposed acute radiculopathy, concurrent lumbosacral canal stenosis with peripheral polyneuropathy, and previous surgeries (eg, laminectomy, ulnar transposition, carpal tunnel release). Elderly patients with diabetes, in particular, present a dilemma because both age-related changes and concurrent polyneuropathy can reduce the diagnostic accuracy of the examination.

**The tester’s expertise affects the results of electrodiagnostic testing**

**TABLE 3****The Cleveland Clinic Foundation electrodiagnostic laboratory guidelines for patients taking anticoagulants**

MEDICATION	DIRECTIONS
<b>Warfarin</b>	Stop warfarin at least 3 days (> 72 hours) before the study A pretest partial prothrombin time (PTT) and international normalized ratio (INR) is not necessary if this precaution is taken
<b>Unfractionated heparin</b> (intravenous)	Stop drip at least 6 hours before the study A PTT/INR is not necessary if this precaution is taken
<b>Low-molecular-weight heparin*</b> (full dose, subcutaneous)	Stop at least 12 hours before the study
<b>Low-molecular-weight heparins*</b> (low dose, subcutaneous for prophylaxis)	No special precautions needed
<b>Aspirin, nonsteroidal anti-inflammatory drugs, clopidogrel</b>	No special precautions needed

\*Enoxaparin, dalteparin, tinzaparin

**Patients must cooperate**

Though generally well tolerated, the electrodiagnostic examination requires good patient cooperation. Poor patient cooperation can limit the usefulness of the examination.

Intolerance is in most cases limited only to one part of the test. The value of limiting the electrodiagnostic examination to one of its components varies from situation to situation, and this decision is best left to the electrodiagnostician. However, as a general rule, no firm diagnosis can be reached on the basis of only one component of the electrodiagnostic examination.

**REPEATING THE ELECTRODIAGNOSTIC EXAMINATION**

The reasons for repeating an electrodiagnostic examination are:

- To further delineate the underlying pathophysiology of an acute injury
- To reassess symptoms arising in a new distribution
- To reassess substantial progression of previous symptoms
- To document the degree of recovery.  
With the exception of rapidly progressive

neuromuscular diseases such as early Guillain-Barré syndrome or early amyotrophic lateral sclerosis, repeating the electrodiagnostic examination within 6 months is of little or no diagnostic value.

**SPECIAL CONSIDERATIONS**

There are some special considerations when ordering an electrodiagnostic examination.<sup>21</sup>

**Implantable cardioverter-defibrillators.** It is imperative to notify the laboratory if the patient has an implantable cardioverter-defibrillator or a pacemaker, as nerve conduction studies can cause a defibrillator to fire. To prevent this, arrangements need to be made for deactivating the defibrillator and for providing cardiac monitoring.

Regular pacemakers generally require no special precaution, but the examination will detect their activity, which should be recognized as an artifact.

**Anticoagulation.** Warfarin therapy (but not antiplatelet agents) is an absolute contraindication to a needle electrode examination in our laboratory, although this rule is not universally accepted. Potential complications include hematomas and compartment syn-

**Poor patient cooperation limits the usefulness of electrodiagnostic testing**



dromes, leading to permanent nerve and, especially, muscle damage. Thus, unless notified otherwise, patients should be instructed verbally and in writing to talk to their primary physician about stopping anticoagulants before an electrodiagnostic examination.

TABLE 3 lists guidelines for patients on oral or intravenous anticoagulant agents.

**Overly anxious patients** may need additional preparation, such as diazepam 5 to 10 mg or lorazepam 2 mg orally 30 minutes before the study. Patients who use daily analgesics can take their regular doses. Additional doses or supplementary narcotics are not of proven benefit.

**Medications that can interfere with results.** If an electrodiagnostic examination is ordered to evaluate the neuromuscular junction (eg, for myasthenia gravis or Lambert-

Eaton myasthenic syndrome), then medications such as pyridostigmine should be stopped at least 12 hours before the study.

### Complications of the examination: What to tell the patient

If the precautionary guidelines are adhered to, there are few if any serious complications associated with this procedure.<sup>22</sup> Sterile single-use needles are always used, and strict electrical safety measures are always followed. Bleeding is minimal, as are skin infections, even in diabetic and immune-compromised patients.

There are no restrictions on activities (eg, driving) immediately after the examination, although immediate heavy muscle use is discouraged.



## REFERENCES

- Dumitru D. *Electrodiagnostic Medicine*. Philadelphia: Mosby; 1995.
- Lai H, Mitsumoto H. Muscle physiology and pathophysiology. In: Levin K, Lüders H, editors. *Comprehensive Clinical Neurophysiology*. Philadelphia: W.B. Saunders; 2000:82–83.
- Levin K. L5 radiculopathy with reduced superficial peroneal sensory responses: intraspinal and extraspinal causes. *Muscle Nerve* 1998; 21:3–7.
- Wilbourn A, Ferrante M. Clinical electromyography. In: Joynt R, Griggs R, editors. *Clinical Neurology*. Vol 1. Philadelphia: Lippincott-Raven; 1997:1–78.
- Waylonis GW. Electromyographic findings in chronic cervical radicular syndromes. *Arch Phys Med Rehabil* 1968; 49:407–412.
- Morgan G, Wilbourn AJ. Cervical radiculopathy and coexisting distal entrapment neuropathies: double-crush syndromes? *Neurology* 1998; 50:78–83.
- Aminoff MJ. *Electromyography in Clinical Practice: Clinical and Electrodiagnostic Aspects of Neuromuscular Disease*. 3rd ed. New York: Churchill Livingstone; 1998.
- Wilbourn A. How can electromyography help you? *Postgrad Med* 1983; 73:187–195.
- Ferrante M, Wilbourn A. Plexopathies. In: Levin K, Lüders H, editors. *Comprehensive Clinical Neurophysiology*. Philadelphia: W.B. Saunders; 2000:201–214.
- Padua L, Padua R, Lo Monaco M, Aprile I, Tonali P. Multiperspective assessment of carpal tunnel syndrome: a multicenter study. *Italian CTS Study Group*. *Neurology* 1999; 53:1654–1659.
- Preston DC. Distal median neuropathies. *Neurol Clin* 1999; 17:407–424.
- Aulisa L, Tamburrelli F, Padua R, Romanini E, Lo Monaco M, Padua L. Carpal tunnel syndrome: indication for surgical treatment based on electrophysiologic study. *J Hand Surg [Am]* 1998; 23:687–691.
- Padua L, Padua R, Aprile I, Pasqualetti P, Tonali P, Italian Carpal Tunnel Syndrome Study Group. Multiperspective follow-up of untreated carpal tunnel syndrome: a multicenter study. *Neurology* 2001; 56:1459–1466.
- Posner MA. Compressive neuropathies of the ulnar nerve at the elbow and wrist. *Instr Course Lect* 2000; 49:305–317.
- Kimura J. *Electrodiagnosis in Diseases of Nerve and Muscle*. 3rd ed. New York: Oxford University Press, 2001:409–438.
- Thomas PK. Classification and electrodiagnosis of hereditary neuropathies. In: Brown W, Bolton C, editors. *Clinical Electromyography*. Boston: Butterworth; 1987:179–200.
- Albers J. Inflammatory demyelinating polyradiculoneuropathy. In: Brown W, Bolton C, editors. *Clinical Electromyography*. Boston: Butterworth; 1987:211–214.
- Sumner CJ, Sheth S, Griffin JW, Cornblath DR, Polydefkis M. The spectrum of neuropathy in diabetes and impaired glucose tolerance. *Neurology* 2003; 60:108–111.
- Levin K, Lüders H. *Comprehensive Clinical Neurophysiology*. Philadelphia: W.B. Saunders; 2000.
- Ferrante M, Wilbourn A. Myopathies. In: Levin K, Lüders H, eds. *Comprehensive Clinical Neurophysiology*. Philadelphia: W.B. Saunders Company; 2000:251–256.
- American Association of Electrodiagnostic Medicine. Guidelines in electrodiagnostic medicine. *Muscle Nerve* 1999; 22:S53–S58.
- Al-Shekhlee A, Shapiro BE, Preston DC. Iatrogenic complications and risks of nerve conduction studies and needle electromyography. *Muscle Nerve* 2003; 27:517–526.

ADDRESS: Kamal R. Chémali, MD, Department of Neurology, S90, The Cleveland Clinic Foundation, 9500 Euclid Avenue, Cleveland, OH 44195; e-mail chemalk@ccf.org.

Visit our web site at <http://www.ccmj.org>

Contact us by e-mail at  
[ccjm@ccf.org](mailto:ccjm@ccf.org)

